

Review Article

Unrecognized Myofascial Components of Pediatric Complex Pain: myoActivation, a Structured Solution for Assessment and Management

Gillian R Lauder^{1,2*}, Jack Huang³ and Nicholas C West¹

¹Department of Anesthesiology, Pharmacology & Therapeutics, University of British Columbia, Vancouver, BC, Canada

²Anesthesia Department, BC Children's Hospital, Vancouver, BC, Canada

³Faculty of Medicine, University of British Columbia, Vancouver, BC, Canada

***Address for Correspondence:** Gillian Lauder, Department of Anesthesia, BC Children's Hospital, 4480 Oak Street, Vancouver, BC, V6H 3V4, Canada, Tel: 604-875-2345; Local 5955; Fax: 604-875-2767; E-mail: glauder@cw.bc.ca

Received: 09 August 2019; **Accepted:** 17 September 2019; **Published:** 18 September 2019

Citation of this article: Lauder, GR., Huang, J., West, NC. (2019) Unrecognized Myofascial Components of Pediatric Complex Pain: myoActivation, a Structured Solution for Assessment and Management. *Curr Trends Med*, 1(1): 001-016.

Copyright: © 2019 Lauder, GR, et al. This is an open access article distributed under the Creative Commons Attribution License, which permits unrestricted use, distribution, and reproduction in any medium, provided the original work is properly cited.

ABSTRACT

Chronic pain is a complex biopsychosocial phenomenon, which confers significant distress and poor quality of life to at least 6% of the pediatric population. Biological constituents of chronic pain arise from various sources: nociceptive, inflammatory, neuropathic, myofascial, as well as peripheral and central sensitization. Chronic myofascial pain arises from dysfunction related to skeletal muscles, fascia and scars. This may be related to a sedentary lifestyle, Western diet, myofascial injury but also musculoskeletal overuse. Chronic myofascial pain is often unrecognized and misdiagnosed, especially in children.

myoActivation is a novel structured process of assessment and treatment designed to recognize and treat myofascial components of chronic pain. myoActivation includes: a comprehensive timeline of trauma history, and a unique, quick and reproducible assessment followed by therapeutic intervention. myoActivation combines effective myofascial pain therapies, including trigger point injections, fascial release and subcision (scar release). myoActivation can be used as one component in the biopsychosocial approach to chronic pain management. The adult process will often need to be adapted to accommodate pediatric developmental and psychological profiles.

This review outlines the importance of nutrition and exercise on skeletal muscle health and some other strategies important in managing pediatric chronic myofascial pain. myoActivation provides an effective, low-cost, non-pharmacological tool to diagnose and treat the myofascial components of pediatric chronic pain. Case studies will demonstrate how to adapt the adult myoActivation process to the pediatric population. The conservative strategies and myoActivation process described require appropriately controlled research studies to fully demonstrate the benefits highlighted in this case series.

Keywords: Pediatric pain, Chronic myofascial pain, myoActivation, Multidisciplinary treatment, nutrition/exercise

Introduction

The prevalence of moderate to severe chronic pain is estimated to be around 19% in European adults [1] and 6-37% in the pediatric population [2-6] with 5-6% reporting moderate or severe chronic pain that significantly impacts their physical, psychological and social functioning [3,7-9]. Biological factors that contribute to the

generation of chronic pain include: inflammation, peripheral and central sensitization, neuropathic and myofascial dysfunction [10]. Chronic pain of childhood is a complex biopsychosocial phenomenon because pain is a highly subjective sensation influenced by biological, psychological and social factors (Figure 1). No two children with chronic pain are the same. Two thirds of pediatric patients report a precipitating event to their chronic myofascial pain, which is most

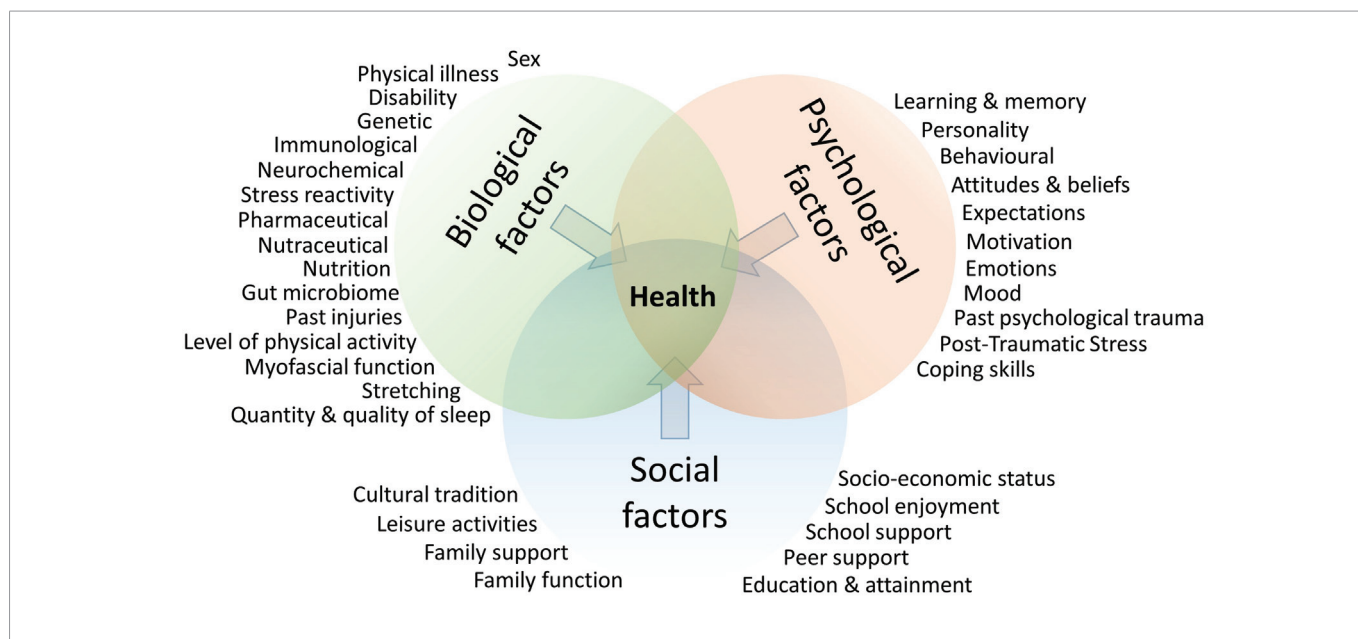


Figure 1: The biopsychosocial contributors to chronic pain (based on Lauder et al [10]).

commonly injury, followed by chronic disease, infection or illness. Surgery is reported to be the precipitating event in 4.7% of children [11]. Chronic pain has a myriad of negative effects on the development of children and adolescents, including poor school attendance, sleep disturbance, decreased social activities, and higher levels of stress and mood disturbances [12,13]. This is associated with considerable costs in terms of healthcare expenditure, family work day losses and loss of productivity [14–17]. The risk of progressing to a life of chronic pain in adulthood is related to the experience of chronic pain as a child or adolescent [18–24].

Children and adolescents afflicted with chronic pain are often referred to a chronic pain management service having previously seen many physicians and other healthcare providers. They undergo many consultations and many investigations aimed at exclusion of a remedial cause for the pain. This often prolonged period of time in consultation culminates in a cascade of negative results. This “diagnostic vacuum” [25] leaves many parents feeling helpless and not willing to accept a primary diagnosis of chronic pain [26]. This arduous, stressful and time-consuming process shapes or mis-shapes parent and child cognitions on pain etiology and management. Children and adolescents may present to the chronic pain service (CPS) with no etiological diagnosis for their pain problem. However, after full review of the pain history, timeline of trauma and examination, many of these children and adolescents are diagnosed with a myofascial component to their pain.

Chronic myofascial pain (CMP) combines fascial dysfunction and musculoskeletal pain (pain related to joints, bones or muscles) [27]. CMP is characterized by deep pain in a non-dermatomal distribution, peripheral sensitization, referred pain and central sensitization [10]. The exact etiology of CMP is unclear. However, it is thought that muscle trauma, skeletal asymmetry, repetitive muscle stress, inflammation and metabolic disturbances can all contribute to myofascial pain [28,29]. Myofascial pain is associated with myofascial

trigger points (MTPs), muscles in sustained contraction and palpable pain points. An MTP is a localized, hyperirritable nodule in palpable, taut skeletal muscle fibres. The presence of MTPs is associated with muscle tenderness, weakness and functional limitation [30,31]. As scars cause fascial tethering and dysfunction, they also constitute an important etiological factor in myofascial pain [32,33].

CMP is common in the general adult population, affecting up to 45% in men and 54% in women [34,35]. CMP is the most prevalent cause of chronic health issues and health care utilization [36] and is a major cause of disability, affecting up to 20% of adults [37]. CMP is also common in the pediatric population and its prevalence has increased since the 1980s [38]. Musculoskeletal pain is a common cause of pain in adolescents ranging from 30-65% [39–43]. Between 4-40% of adolescents report limb pain and 14-24% complain of low back pain [3]. The prevalence of pediatric CMP increases with increasing age [38,44–47] and is more common in females [3,48].

Methods: myoActivation Assessment & Treatment Techniques

myoActivation is a structured and reproducible system of assessment and treatment designed to reduce myofascial components of chronic pain. Assessment relies on recognizing the importance of the timeline of lifetime trauma and the mechanisms of injury. The earliest or most significant physical trauma in childhood is often an inciting event for development of chronic myofascial pain and this needs to be elicited in detail. The history should capture any motor vehicle accidents, falls, fractures, major and minor surgeries, and scars as well as the consequences and healing process of these traumatic events.

The structured physical examination consists of postural evaluation and a core set of systematized and reproducible biomechanical movement tests looking for the most restricted or painful movement to locate the most important myofascial site. This

determines the most important tissues to treat first. Depending on the patient presentation and the site of perceived pain, extra tests (known as regional tests) are utilized for areas including the neck, shoulder, and peripheral limbs. This structured assessment relies on excellent observational skills and comprehensive knowledge of anatomy.

A review of the basics of myoActivation can be found at <https://www.intechopen.com/online-first/myoactivation-a-structured-process-for-chronic-pain-resolution> [10].

Assessment determines the most important muscles that are in sustained contraction. Dry-needling of the palpable pain points or MTP's in these muscles (myoActivation) induces a state of relaxation in that muscle associated with immediate decrease in pain and improved range of movement. Fine hollow bore needles are inserted into palpable pain points not only in muscle, but also ligaments, tendons, subcutaneous fascia, and scar tissue. The mechanism for pain relief from needling to achieve muscle activation and release of fascia or scars in tension is complex. It has been postulated to involve neural, vascular, chemical and endocrine changes in the local environment of the affected tissue [10].

After each individual myofascial area is treated, movement tests are repeated to demonstrate immediate change and direct the assessor to the next most important target area. Several repeated assessment and treatment cycles occur during each myoActivation session. The purpose of these catenated cycles is to help unravel multiple sources that contribute to the full myofascial pain presentation. Immediate treatment responses occur, which include overall reduction in pain, as well as increased flexibility and fluidity of movement. The following case series will demonstrate the spectrum of care required to safely adapt the adult myoActivation process to treat children and adolescents with a myofascial component of their chronic pain.

Results: Pediatric myoActivation Case Series

Eight of the most recently discharged patients aged 7 to 16 (Table 1), treated with myoActivation are highlighted in this case series to emphasize the utility of myoActivation, but also, to show that careful consideration is needed to ensure minimal distress related to procedural anxiety and needle aversion in this vulnerable population. Ethical approval was obtained for this case series from the University of British Columbia / Children's & Women's Health Centre of British Columbia Research Ethics Board (ref H19-00279, PI G Lauder, date of approval 26-Jul-2019).

All eight patients were referred to the Complex Pain Service (CPS) clinic for the management of pain refractory to standard treatment modalities. Each patient was enrolled in a multi-disciplinary management process [Physiotherapy, Psychology & Pharmacology (3P)] prior to institution of myoActivation. Each patient was referred to mycarepath.ca [49] for education and self-management strategies to help with chronic pain, especially with respect to pacing of activities and help with sleep.

Case 1: Standard myoActivation assessment & treatment using non-pharmacological distraction techniques

A 12-year old, 77kg, female was referred to the CPS for chronic back pain of 6 years in duration. Her pain began with tailbone discomfort and sore legs but no obvious traumatic or inciting event was identified. At presentation, the pain was localized to the back, extending the entire midline spine with occasional radiation down to the lower legs bilaterally. Two years after onset, she began to complain of soreness in her calves and headaches in addition to her back pain. Her overall pain was worsened with menarche. She had no pain free times with pain aggravated by exercise, standing, or sitting for long

Table 1: Case series summary.

#	Description	Patient	Chronic pain presentation
1	Standard myoActivation assessment & treatment using non-pharmacological distraction techniques	12-year old, 77kg, female	Back pain for 6 years
2	myoActivation using oral sedation	11-year old, 39kg, female	Bilateral neck pain present since an MVA 6 years previously
3	Non-verbal patient	16-year old, 69kg, female with autism, global dev. delay and seizures	Worsening right leg pain after tibial tubercle osteotomy and realignment for patellofemoral instability 1 year previously
4	myoActivation assessment only with no intervention, used to guide physiotherapy and massage	14-year old, 88kg, female	Left knee pain after fall one year previously
5	Unusual presentation of myofascial dysfunction	7-year old, 23kg female with thrombocytopenia with absent radius syndrome	Cold-induced bilateral hand and wrist pain present for the previous 2 years
6	Standard myoActivation assessment & treatment of a neuropathic pain	16-year old, 110kg male	Right wrist pain of 5 years duration with presumed diagnosis of ulnar nerve neuropathy
7	Standard myoActivation assessment & treatment of abdominal wall pain	15-year old, 85kg, male	Left lower quadrant abdominal pain of 14 months duration; diagnosis of abdominal wall pain with no inciting event
8	Standard myoActivation assessment & treatment of multisite pain	11-year old, 38 kg female	Multisite chronic pain of 2 years duration; diagnosis of "Pain Syndrome" focused to the anterior chest wall with no apparent inciting event

Note: age, weight and sex have been listed as a guide for readers to find applicable cases; there is no intention to suggest a link between any of these factors and treatment outcomes.

periods of time. She stated that she had become irritable and was generally fatigued, especially with pain flares. She had been absent from school for 14 days in the previous 3 months. She reported that pain also affected her sleep, concentration and cognitive abilities. Her lifetime trauma history revealed a motor vehicle accident (MVA) at age 7, which occurred after the onset of her chronic pain. She had also fallen at age 2, with scars on her left knee and her chin as a result of the injury. She was otherwise healthy and her family history was unremarkable.

She was assessed by pediatrics, neurology and neurosurgery. Previous classical examination, imaging (X-ray and MRI) and bloodwork revealed no remedial cause of her pain. Prior to referral to CPS, she was already integrated with physiotherapy (PT), massage therapy (MT) and chiropractic care. Medications at initial assessment included diclofenac 50 mg BID, pregabalin 150 mg BID, calcium supplementation, and melatonin 40 mg QHS. myoActivation examination revealed a myofascial component to her pain. She was enrolled in the 3P care plan. Her calcium supplementation was stopped, and she was started on magnesium bisglycinate, Vitamin D₃ and Vitamin K₂ supplements (MgBis/K2/D3), other medications were not changed. In view of increased body mass index, advice on an anti-inflammatory diet and omega-3 supplementation was given to the family. Written myoActivation information was given to the family. One month later, there was a reduction in pain with improved fluidity of movements. She also reported improved mood. Her medications included pregabalin 150 mg BID, muscle health supplements, melatonin 20 mg HS and diclofenac 50 mg BID.

It was deemed appropriate to proceed with myoActivation at the one month follow up visit based on the patient's calm demeanor. Written consent was obtained. Distraction techniques and vapocoolant spray were used to minimize procedural pain. The coccygeal fascia and the right paraspinal muscles were released based on core BASE tests [10]. After this first myoActivation session the patient experienced immediate improvement and quoted "Oh my god, this is amazing." The patient was advised to start slowly weaning her pregabalin daily dose. One month after this myoActivation session the patient reported less pain and feeling much better. She reported being much more engaged with school and social activities. However, she still endorsed issues with sleep, particularly staying asleep. Current medications were pregabalin 25 mg AM and 150 mg HS, melatonin 20 mg HS, diclofenac 50 mg BID and MgBis/K2/D3. The patient was recommended to further wean pregabalin and stop diclofenac.

The patient underwent three sessions of myoActivation in total. At the time of the third myoActivation session her medications were pregabalin 25 mg AM and 100 mg HS, melatonin 20 mg HS and MgBis/K2/D3. Her quote at the end of the third myoActivation session was "I'm not sure I have ever felt this happy in 6 years. You know when the first warm sun after winter is over? That's what it feels like. It feels absolutely amazing." At the time of discharge 5 months after initial assessment she had no pain, able to function physically with no restrictions or pain and was attending school full time. She was on no analgesic medications and advised to slowly wean MgBis/K2/D3.

Key points: This case demonstrates that in an appropriately selected and motivated 12-year-old that the adult myoActivation technique can be utilized with minimal adaptation. It is clear that

providing an answer to pain, which had previously been elusive, is also important in terms of trust with the care team and also a motivator to proceed with myoActivation. This case also demonstrates the dramatic change in pain and subsequent ability to reduce systemic analgesia related to institution of the 3P approach, massage, dietary advice, MgBis/K2/D3 and myoActivation. The improvement in quality of life, with this approach, is not isolated to this case but repeated in daily practice for many patients presenting with CMP to the CPS. In this age group it is vitally important to ensure ongoing consent for myoActivation session so that the child feels in control at all times. The unravelling process of myoActivation, through catenated cycles, is essential to identify multiple and different areas of anatomical distortion contributing to the chronic myofascial pain [10]; hence, why it is important to have a child awake and co-operative. Each cycle of intervention provides immediate feedback of the treatment to both the practitioner and the patient, with retesting that identifies the next important myofascial area for treatment. Not doing too much at any one time, especially on the first myoActivation treatment, is important to maintain trust and engagement. Immediate changes in pain, increased range of motion and increased fluidity of movement are major motivators for children and parents to proceed with ongoing myoActivation sessions. Usually 2-4 are required for full pain resolution. For younger children, needle averse or non-verbal children, the process followed for this case would not be possible and it needs to be adapted to avoid traumatizing the child.

Case 2: myoActivation using oral sedation

An 11-year old, 39kg, female was seen in the CPS for chronic bilateral neck pain present since an MVA six years previously. She had been asleep in her booster seat when the car experienced a rapid deceleration and head-on collision. No medical issues were apparent at the time of ER presentation immediately after the MVA. The neck pain started 2 months after the accident with no intervening inciting event identified. At initial presentation, the patient reported no pain free times, with the pain worse in the evening. The pain was aggravated by physical activity. She had difficulty sleeping as pain would often awaken her, and she reported irritability and a decreased ability to concentrate at school because of the pain. Her lifetime trauma history revealed an injury to her left arm while stretching in ballet 3 years earlier, a bent right elbow while playing tennis 1 year earlier. She had scars on her right elbow, right face and left elbow. She had imaging done through the chiropractor and her family physician, which was normal. Medications at initial assessment included Advil and robaxacet, magnesium and vitamin D. myoActivation examination at this time confirmed a myofascial component to her chronic pain. She was started on MgBis/K2/D3 supplements and enrolled in the 3P care plan. At the 1-month follow-up visit the patient reported improvement with less neck pain. She felt more relaxed and overall better. She was doing ballet classes 3-4 times/week. She was not on any analgesic medications. The 3P process with massage therapy was ongoing. Two months later, she reported feeling much better overall, but her shoulder pains were disturbing her sleep and ballet classes, and she needed nightly massages from her mother to ease this discomfort. On myoActivation examination, the number of muscles in sustained contraction was markedly reduced compared with initial assessment. myoActivation was planned to improve recovery time. Lorazepam was administered one-hour pre-procedure for anxiolysis as the patient was needle averse. Topical anesthetic was applied to the right knee scar. Oral midazolam was administered

20 minutes pre-procedure to further decrease procedural and needle anxiety. Distraction techniques and vapocoolant spray were also used to minimize procedural pain. Based on core BASE tests and following intervention and retesting catenated cycles [10], the coccygeal fascia and the right knee scar were released and the right QL, right hamstring and bilateral trapezius muscles were activated. At the follow-up appointment 3 months later, the patient reported feeling great and no longer needing nightly massages. She was progressing with fun activities and with much improved sleep. With each subsequent myoActivation she required less oral sedation. The patient underwent three sessions of myoActivation in total. She became less needle averse after experiencing the beneficial effects of the myoActivation procedure. In fact, she was even keen to do the last session of myoActivation. At this point in her care, she transitioned from weekly MT to biweekly and she did not require PT any longer. At 13 months from initial assessment, she was discharged from the CPS with instructions to slowly wean.

Key points: Children who are needle averse may require pharmacotherapy for anxiolysis in addition to distraction techniques and topical anesthetics. Prior to their myoActivation appointment, it may be helpful to show the patient the equipment that will be used for the procedure, including the needle. If the patient is agreeable, it may even be beneficial to offer a trial of single needle insertion to experience the needling process. Using pressure and stretch techniques at the site of and immediately prior to needle insertion it is our experience that children do not feel the insertion. This is beneficial to give an experiential understanding of the procedure to have less anxiety leading up to a myoActivation appointment. In this case, our patient realized and understood the benefits of the needling procedure, and experienced immediate response to treatment and her attitude towards needles gradually changed. However, when performing interventional procedures, clinicians must be aware of certain red flag signs that may signal that the interventional procedure may never be appropriate for a patient. Examples include exaggerated anxiety at the prospect of an interventional techniques, heightened response to intravenous access or abnormal response (emotional or pain escalation) to the intervention. "Physician failure to understand the nature of suffering can result in medical intervention (though technically adequate) that not only fails to relieve suffering but becomes a source of suffering itself" [50]. Additionally, patients with chronic pain may become dependent on interventional techniques to provide pain relief. The clinician must emphasize the importance of the 3P approach prior to starting interventional procedures and to continually reinforce this concept throughout the course of treatment.

Case 3: Non-verbal patient

A 16-year old, 69kg, non-verbal female with autism, global developmental delay and seizures was referred to the CPS for assessment and management of worsening right leg pain after right tibial tubercle osteotomy and realignment for patellofemoral instability one year earlier. Her pain had considerably worsened in the 6 weeks prior to her initial CPS appointment. Her postoperative X-rays confirmed normal healing but she developed worsening pain. There was no specific pain pattern, with the pain occurring daily and restricting her activity level and school attendance. She required 2 caregivers at school and at home. Sleep was also affected. Her epilepsy had become worse with sleep interruptions and pain to the point that anti-seizure medication dosage had to be increased by her neurologist.

When a pain episode occurred, she would become rigid then fall to the ground if nobody was there to prevent it. There were no changes in skin colour or temperature and no edema. Acetaminophen, ibuprofen, and naproxen had been trialed but were not effective. She was integrated with PT and MT prior to referral.

A complete myoActivation assessment exam could not be performed given her non-verbal status, level of cooperation and inability to follow commands for specific tasks. However, she appeared to have tenderness and palpable pain points centred to the right thigh so she was started on MgBis/K2/D3 supplements. At the 1-week follow-up appointment, her pain was reported to be much improved and she appeared much happier. She now had only 1 caregiver at school and at home. Her sleep had also improved. myoActivation scar release was done on the right side under topical anesthesia. Post-treatment assessment revealed improved mobility.

She was seen in the clinic one month later. Her caregiver reported that her pain condition was overall better but still had spasms in the right leg that were worse in the morning and at night before sleep. On examination, she had tenderness in the right rectus femoris, right vastus lateralis, right TFL, right adductor and left iliopsoas. Pregabalin was recommended to help improve her sleep. Over the course of 3 months, her pregabalin and magnesium dose were increased with improvement in spasms, ambulation and sleep. However, she still had isolated spasms of her right adductor and 2 sessions of myoActivation were done to re-release the scar on her right knee and her right adductor muscle. At the 14-month follow-up visit, her caregiver reported that she was doing very well, with much improved sleep and school attendance. She was also ambulating and was able to walk up to 1.5 km. At the last appointment, she was on Pregabalin 25 mg AM and 50 mg HS and had stopped MgBis/K2/D3 supplementation. Given her excellent progress she was discharged from CPS with instructions to slowly wean pregabalin.

Key points: It is difficult to assess pain in a non-verbal patient. In addition, children and adolescents with developmental delay may not be able to participate in a myoActivation examination. Therefore, the pain physician may have to rely heavily on parent and carer observations as well as clinical experience and acumen to determine if there is a myofascial component to the patient's pain and to target the culprit tissue appropriately.

Case 4: myoActivation assessment with no myoActivation intervention used to guide physiotherapy and massage

A 14-year old, 88.3kg, female developed chronic left knee pain after falling onto her left knee approximately one year earlier. She was able to weight bear immediately after the traumatic incident but subsequently developed pain and a limp. The pain was localized to the medial knee and was of a throbbing quality, exacerbated by activity and relieved by icing. She had been referred to orthopedic surgery and was investigated including MRI, X-rays and exploratory arthroscopy, which were all negative for a recognizable pathology. Prior to referral to CPS, she had tried PT and used over-the-counter anti-inflammatory and analgesics for pain control. Her past medical history included a right knee injury at age 10 that had resolved uneventfully, two occasions of falling onto the coccyx with no residual deficits. She was otherwise healthy and family history was non-contributory. Medications included acetaminophen and ibuprofen PRN.

Initial myoActivation assessment revealed a myofascial component to her pain with an antalgic gait, multiple muscles in sustained contraction, fascial tension around the left lateral malleolus and two scars on her left knee. She was instructed to continue with weekly PT and MT, targeting the muscles found in sustained contraction. Psychology was recommended to complete the 3P approach to chronic pain. In view of increased body mass index, advice on an anti-inflammatory diet and omega-3 supplementation was given to the family. She was started on MgBis/K2/D3. At the 3-month follow-up appointment, she reported less pain in her knee, improved range of motion and decreased limp. She was no longer taking acetaminophen or ibuprofen. She had marked improvement in gait, posture, balance and fluidity of movement. She reported only mild hip pain after heavy exercise. Her BASE exam revealed no restrictions with any movement. Given the drastic improvement in her pain state and function with PT and MT, no myofascial and scar release was required. She was discharged from the CPS with a recommendation to wean MgBis/K2/D3.

Key points: Motivated patients who take charge in their recovery may only need conservative therapy with MT, PT and muscle health supplements. This case highlights the importance of this first-line therapy before moving onto interventional methods. It also illustrates that the myoActivation examination is useful to diagnose myofascial dysfunction then show changes with subsequent follow up examinations which allow targeted PT and MT.

Case 5: Unusual presentation of myofascial dysfunction

A 7-year old, 23kg female with thrombocytopenia with absent radius syndrome was referred to the CPS for the assessment and management of cold-induced bilateral hand and wrist pain that had been present for the previous 2 years. The referral was principally for advice on pain management prior to more invasive investigations to rule out a vascular cause for pain. The pain was associated with purple discoloration of the skin. The symptoms were worse on the right hand and mainly affected the ring and middle fingers. The pain pattern was variable. Cold temperature was the main aggravator of pain while heat relieved it. The patient reported trouble falling asleep and was afraid to move hands due to pain. Otherwise, she had good physical and social functions. She was not on any medications. Her past medical history was significant for two surgeries on both hands and wrists, one at 9 months old and one at 18 months (right side only) for centralization of the radii. She was involved in multiple extracurricular activities (dance and swimming) and was doing well at school. Family history was non-contributory.

On examination both hands were warm and well perfused with bilateral ulnar, radial and brachial pulses. The scars from surgery were more prominent and tethered on the right side but it was unclear if these were impacting her pain presentation. Multiple muscle trigger points were found on myoActivation examination. At the 1-month follow-up, she reported no difference in the frequency and intensity of the pain despite starting MgBis/K2/D3 and PT, but was awaiting MT and psychology support. myoActivation was discussed with the family and the referring plastics team, given the right-sided predominance of myofascial distortions and worse symptoms of her right hand. myoActivation under monitored procedural sedation was planned. The scars on both wrists were released and the right

paraspinal, left rectus femoris and left vastus lateralis were activated. There were no complications. Two months after myoActivation, the patient reported improved pain symptoms with no pain while skiing and playing outside in cold temperatures. She was discharged from the care of the CPS with instructions to wean MgBis/K2/D3.

Key points: This case demonstrates that the myoActivation technique is feasible, but needs to be adapted to be performed under sedation in younger age groups. The risk/benefit and cost analysis of the potential pain reduction versus risks of anesthesia need to be considered at all times. However, for this child, her pain resolution has meant that she will not be exposed to investigation for a vascular cause to her presenting symptoms.

Case 6: Standard myoActivation assessment & treatment of a neuropathic type pain

A 16-year old, 110kg male was referred to the CPS for management of chronic right wrist pain of 5 years duration with a presumed diagnosis of ulnar nerve neuropathy. He underwent removal of an osteochondroma of his right wrist 5 years previously. He had had pain since the time of surgery. He had been right hand dominant but learnt to write with his left hand to minimize pain. The pain was localized to the right wrist, extending to the lateral two ipsilateral fingers. He had no pain free times with pain aggravated by exercise and using his wrist. He believed he had "nerve damage". He stated that he had become irritable, depressed and anxious about his pain. He had been completely absent from school for the previous 3 months complaining about inability to concentrate due to pain. He reported that pain also affected his ability to fall and stay asleep. His lifetime trauma history revealed no other injuries or MVAs. His only scar was that related to his surgery. He had been taking morphine, gabapentin and naproxen but had weaned himself off them with the help of regular CBD oil. He was otherwise healthy and his family history was unremarkable.

He was assessed by his orthopedic surgeon and neurology. Previous classical examination, imaging (X-rays, EMG and nerve conduction studies and MRI) and bloodwork revealed no remedial cause of his pain. Prior to referral to CPS, he was already integrated with regular PT and intermittent MT. Medications at initial assessment were CBD oil only. myoActivation examination revealed a myofascial component to his pain. He was enrolled in the 3P care plan. He was started on MgBis/K2/D3, his current CBD oil dosage was not changed. In view of increased body mass index, advice on an anti-inflammatory diet and omega-3 supplementation was given to the family. Written myoActivation information was given to the family. One month later, there was a reduction in pain with improved fluidity of movements. He also reported improved mood and sleep. It was deemed appropriate to proceed with myoActivation at this one month follow up visit based on his calm manner. Written consent was obtained. Distraction techniques and vapocoolant spray were used to minimize procedural pain. The right external oblique, right rectus abdominis and scar on the right wrist were released based on core BASE tests [10]. After this first myoActivation session the patient experienced immediate improvement. The patient was advised to start weaning his CBD oil daily dose. One month after this myoActivation session the patient reported no pain in his wrist with dramatic improvements in his mood, motivation and ability to return to school. He had been able to reduce his daily dose of CBD oil. His

only complaint was that he had some difficulty doing press ups in the gym because of right shoulder pain. Repeat myoActivation was done using regional tests for shoulder function. After activation of the right serratus anterior he demonstrated that he could do a push up without pain. His quote at the end of this second myoActivation session was “no pain, I feel like air”. At the time of discharge 4 months after initial assessment he had no pain, he was able to function physically with no restrictions or pain and was attending school full time. He was discharged from CPS care and advised to slowly wean MgBis/K2/D3.

Key points: This case again demonstrates the dramatic change in long-term pain, mood and function that can be realized with the institution of the 3P approach, massage, dietary changes, MgBis/K2/D3 and myoActivation. This case also demonstrates that even with a presumed neuropathic element to pain, it may well be caused by myofascial dysfunction. It has been emphasized that 2-4 sessions are usually required for full pain resolution. This case demonstrates an important clinical observation commonly seen with myoActivation: that is, the pain site may move from one session to another as multiple sources of myofascial dysfunction are resolved.

Case 7: Standard myoActivation assessment & treatment of abdominal wall pain

A 15-year old, 85kg, male was referred to the CPS for management of left lower quadrant abdominal pain with a 14 month duration with a diagnosis of abdominal wall pain with no inciting event. He was previously fit and healthy. The pain was localized to the left lower quadrant of the abdomen, with no radiation and no other specific abdominal symptoms. His pain was variable and intermittent, but aggravated by exercise. He believed he had “a tear in his abdomen from sports activities”. He reported being grumpy and anxious about his pain. He had been absent from school for 2 days in the previous 3 months due to pain. He reported that pain also affected his ability to fall and stay asleep. His lifetime trauma history revealed no other injuries.

He had a right groin scar from a hernia repair as a baby and bilateral knee scars related to falling off some monkey bars 5 years previously. He took acetaminophen and ibuprofen as required. He was otherwise healthy and his family history was unremarkable.

He was assessed by a general surgeon and his family doctor. Previous classical examination, imaging (abdominal ultrasound) and bloodwork revealed no remedial cause of his pain. myoActivation examination revealed a myofascial component to his pain. He was enrolled in the 3P care plan. He was started on MgBis/K2/D3. Written myoActivation information was given to the family. One month later, there was a reduction in pain with improved fluidity of movements. It was deemed appropriate to proceed with myoActivation at this one month follow up visit based on his calm character. Written consent was obtained. Distraction techniques and vapocoolant spray were used to minimize procedural pain. The left QL, left iliopsoas, and left rectus abdominis were activated and the right sternal fascia was released based on core BASE tests [10]. After this first myoActivation session the patient experienced immediate improvement. The patient was advised to start weaning his CBD oil daily dose. One month after this myoActivation session the patient reported no pain. At follow up 4 months after initial assessment he had no pain, and reported a “real improvement in his health”. He was able to function physically with no restrictions or pain and was attending school full time. He was discharged from CPS care and advised to slowly wean MgBis/K2/D3.

Key points: This case again demonstrates the dramatic change in pain, mood and function that can be realized with the institution of the 3P approach, massage, MgBis/K2/D3 and myoActivation. This case also demonstrates that even abdominal pain may be caused by myofascial dysfunction.

Case 8: Standard myoActivation assessment & treatment of multisite pain

An 11-year old, 38 kg female was referred to the CPS for management of multisite chronic pain of 2 years duration with a diagnosis of “Pain Syndrome” focused to the anterior chest wall with no apparent inciting event. She had been involved in an MVA three years previously, but the family had not linked this MVA to her current pain until directly questioned about the timeline of lifetime trauma. The pain was localized to the right sternum associated with some right sternal prominence. She had pain free times with pain aggravated by exercise and using her right shoulder. She stated that she did not know the cause of her pain. She stated that she had some sadness, mild depression and was very anxious about her pain. She had been absent from school for 20 days in the previous 3 months. She complained about some inability to concentrate due to pain. She reported that pain also affected her ability to fall and stay asleep. Her lifetime trauma history revealed no other injuries. She reported no scars. She had been taking acetaminophen and ibuprofen as required. She was otherwise healthy and her family history was unremarkable.

She was assessed by her orthopedic surgeon and family doctor. Previous classical examination, imaging (X-rays) and bloodwork revealed a prominence of the right sternum, but no remedial cause of her pain. myoActivation examination revealed a number of unreported scars and multiple muscles in sustained contraction. A myofascial component to her pain was diagnosed. She was enrolled in the 3P care plan. She was started on MgBis/K2/D3. Written myoActivation information was given to the family. One month later, there was a reduction in pain with improved fluidity of movements. Her family also reported improved mood and sleep. It was deemed appropriate to proceed with myoActivation at this one month follow up visit based on her stoical character. Written consent was obtained. Distraction techniques, vapocoolant spray and topical anesthetic for scars were used to minimize procedural pain. The right paraspinal and left iliopsoas were activated, four scars and the coccyx fascia were released based on core BASE tests [10]. After this first myoActivation session the patient experienced immediate improvement in pain and flexibility. The patient was advised to continue with the 3P approach. One month after this myoActivation session the patient reported low back pain and knee pain. The right gluteus medius was activated, and the right knee scar was released based on core BASE tests [10]. At the next myoActivation session, one week later, the patient reported right periscapular pain. Repeat myoActivation was done using regional tests for shoulder function. The right serratus anterior was activated, and right sided chest wall scar was released. At the next myoActivation session, one week later, the patient reported no anterior chest pain and no back or periscapular pain. Repeat myoActivation assessments revealed some limitation in squats. Based on core BASE tests the right knee scar was re-released as were the scars on the left thigh and shin. At the time of discharge, 8 months after initial assessment, she had no pain, she was able to function physically with no restrictions or pain and was attending school full time. She was discharged from CPS care and advised to slowly wean MgBis/K2/D3.

Key points: This case demonstrates that pain classed as a “pain syndrome” may well be caused by myofascial dysfunction and this can be discerned from a myofascial assessment and examination. This case also demonstrates the ever changing pain pattern with repeat myoActivation sessions as multiple sources of myofascial dysfunction are resolved. Clearly patients do not remember all their previous traumas and scars, which makes the timeline of trauma as well as full examination to find relevant fascia in tension and scars really important in the diagnostic and therapeutic myoActivation process.

Discussion

Pediatric chronic pain is a complex issue. The impacts of genes, culture, immune function, metabolic status, nutrition, lifestyle, psychosocial status and environment all play a part in its presentation. It is clear that no one modality is going to be the answer to all chronic pain issues. In trying to rationalise why chronic pain is so increasingly prevalent we need to look at grass roots reasons why this may be the case. The mismatch between our evolutionary genes and our present lifestyle seems to make sense in terms of lack of exercise and poor diet. One advantage of the current opioid crisis has been that it has driven a greater focus on non-pharmacological techniques in the complex pain population. myoActivation meets the criteria of an effective, low cost, minimally invasive non-pharmacological technique.

Under-recognized Chronic Myofascial Pain (CMP)

Despite its prevalence, myofascial pain commonly goes undiagnosed in the primary care setting [51]. Musculoskeletal pain is also generally under-diagnosed in adolescents [2,52]. Healthcare providers may be unfamiliar or not trained to diagnose chronic pain, muscle trigger points, palpable pain points and fascia in tension [53–56]. System and practice pressure may also limit the ability to undertake a full history and physical examination [57,58]. Myofascial pain can also mimic other pathologies; for example, myofascial dysfunction of gluteus medius can present as pain in the lumbar area because of its referred pattern, thereby making diagnosis more challenging. Myofascial pain may also be perceived in a site that is not in the immediate vicinity or in the referred pain region of the muscle trigger responsible for pain. There is a specific myofascial pattern for each muscle group, which is known as “the muscle signature” [59]. For example, an MTP in the left posterior quadratus lumborum muscle may present with ipsilateral anterior lower abdominal pain, mimicking appendicitis. Myofascial pain can also affect more than one site concomitantly [43,60,61] leading to multiple and complex presentations. This makes the diagnosis of CMP even more difficult and hence why it is often missed in a clinical encounter [59].

To begin to recognize CMP, it is important to understand what contributes to its development. It is becoming increasingly evident that this may be related to a combination of effects, including genetics, nutrition, immune function, lifestyle, lifetime traumas and the evolutionary mismatch of the human body to rapid environmental and cultural changes.

In his book, “*The Story of the Human Body: Evolution, Health and Disease*” [62], Daniel Lieberman describes how the disparity between the needs of Stone Age bodies and the current modern-day body creates a paradox of increasing longevity, but with a proliferation in the chances of chronic disease. Key evolutionary adaptations that were important for survival on the plains of Africa (bipedalism, socialization, communication, athleticism, different diet

and large brains) have provided many benefits. However, cultural and environmental change has outpaced our ability to adapt, leading to many chronic diseases such as obesity, cardiovascular disease, type 2 diabetes, Alzheimer’s disease, as well as chronic myofascial pain [63]. This necessitates a different approach focusing on exercise and the dietary influences on our gut microbiome.

A normal functioning gut requires a microbiome that maintains and protects the gut lining. Dysbiosis of the gut microbiome is induced by many different factors [64,65]. Dysbiosis of the gut microbiota is associated with compromise of the gut lining and increased permeability facilitating the leakage of endotoxins, lipopolysaccharide (LPS), and other microbial products into the systemic circulation triggering immune responses through the production of free radicals and inflammatory cytokines [66]. LPS induces skeletal muscle inflammation which will [67] trigger a switching of the phenotypic expression of skeletal muscle macrophages [68–70] to secrete nociceptive cytokines. Chronic pain patients also have high levels of pro-inflammatory cytokines in their blood and tissues [71] so it is interesting to contemplate if chronic pain conditions should be added to the list of diseases associated with gut dysbiosis. Attempts at restoring gut function and good microbiome status may have positive impacts on chronic pain and myofascial dysfunction as well as other modern-day diseases. Healthy nutrition (presumed anti-inflammatory and anti-oxidant) [72] is recommended to our patient population because it intuitively makes sense and has no harms, on the presumption that it may positively impact their gut function and microbiome, but evidence to support this is currently very limited.

In evolutionary terms, the human is designed to be physically active and this is borne out by the reported benefits of exercise. Regular exercise reduces mortality, increases longevity, lowers the prevalence of chronic diseases, increases muscular strength, improves endurance, enhances mitochondrial biogenesis [73], increases bone density, changes body mass and fat, lowers sympathetic tone, improves sleep, modulates the hypothalamic pituitary axis (HPA), improves mood, increases endogenous opioids, increases endogenous serotonin, reduces inflammatory cytokines, reduces chronic pain, reduces glial cell activation, and increases anti-inflammatory cytokines in the dorsal horn of the spinal cord [74–79]. The CDC recommends 150 minutes per week of moderate to vigorous activity for health benefits. Children aged 5-17 require 30 minutes per day [80]. Regular physical activity prevents the development of chronic myofascial pain [68] and physically active people are at significantly lower risk of developing chronic pain [81–83]. Moderate, but not vigorous activity, has been associated with lower prevalence of chronic low back pain [84] and chronic widespread musculoskeletal pain [85]. The relationship of exercise to chronic low back pain has a U-shaped relationship with both inactivity and excessive exercise associated with worse pain [81,84]. Long term regular exercise decreases pain behaviours in the mouse model of neuropathic pain [77,86]. An increase in regular activity level in people with existing chronic pain is also associated with improved symptoms [87–96]. Sessions of more than 30 minutes moderate intensity exercise are needed to effect a lower prevalence of chronic pain [81]. However, it is currently not certain exactly what type and frequency of exercise is required to achieve these improvements.

Conversely inactivity is not good for health and its effects have been referred to as the “disease of physical inactivity” [97]. Physical

inactivity is the fourth leading risk factor for global mortality [98]. Lean men who do not exercise have twice the risk of dying as obese men engaged in regular physical activity [99]. Physical inactivity may also be a contributing factor causing pain to become chronic [100]. Sedentary animals exposed to a single session of fatigable exercise demonstrate hyperalgesia [101]. Clinical experience also shows that many patients with chronic pain conditions also show increased pain with onset of an exercise regime [102,103]. Therefore it is important to educate patients on pacing and pain science to minimize the fear of movement and help motivate patients to produce better pain and disability outcomes [89,104].

Optimal functioning of skeletal muscle requires appropriate levels of magnesium, Vitamin D₃ and Vitamin K₂. Clearly healthy nutrition with minimal processed foods would not require vitamin supplementation but our clinical experience has shown that nutraceutical supplementation with magnesium and Vitamin K₂ and D₃ has made a big impact on initial attempts to return to physical functioning for pediatric patients with CMP.

Magnesium is a cofactor in over 300 bodily enzymatic reactions. It is important for mitochondrial membrane stabilization as well as optimal nerve and muscle function [105,106]. The physiological roles of magnesium in skeletal muscle include electrolyte balance, ATP production, RNA/DNA production, protein synthesis, oxygen uptake, fat oxidation and glycogen breakdown. There is a positive association between dietary magnesium and skeletal muscle mass and power [107]. Magnesium also regulates the conversion of Vitamin D to its active form 1,25 OHD, stabilizes nerve cell membranes, is anti-inflammatory, has NMDA receptor antagonist properties, promotes serotonergic production and is a cofactor for the inhibitory neurotransmitter GABA [108]. Normal cellular function requires the appropriate balance of magnesium and calcium. Calcium intake from food and nutraceuticals has exceeded that of magnesium giving an abnormally high body calcium to magnesium balance [109]. Hypomagnesemia or the imbalance of magnesium and calcium ions in the body leads to hyper-contractility of skeletal muscles, muscle dysfunction [110] and a low grade inflammatory state [111] associated with increased reactive oxygen species and inflammatory markers such as IL-6 and CRP.

The recommended intake of magnesium is 300-400 mg/day, but the intake of magnesium has decreased over the last decade to suboptimal levels due to changing dietary patterns and food processing practices [108,109,112,113]. Around 99% of the magnesium in the body is stored in bone and skeletal muscle with less than 1% in serum and red blood cells. This small percentage of total body magnesium in serum means that serum magnesium levels do not accurately reflect the status of total body magnesium stores, making it difficult to know for certain that patients are magnesium deficient.

Vitamin D is a steroid prohormone made through dermal synthesis from sunlight or sourced from the diet. Vitamin D obtained from sun exposure, food, and supplements is biologically inert, it undergoes two hydroxylations in the body for activation. The first occurs in the liver and converts vitamin D to 25-hydroxyvitamin D [25(OH)D], or calcidiol. The second occurs primarily in the kidney and forms the physiologically active 1,25-dihydroxyvitamin D [1,25(OH)₂D], otherwise named calcitriol. Many tissues in the human body have receptors for the active vitamin D metabolite. Vitamin D plays a fundamental physiological role in human health

[114] including immunomodulatory function [115], CNS function [116], cardiovascular health, as well as muscle growth and repair [117]. Many children and adolescents are Vitamin D deficient largely due to an indoor lifestyle and poor dietary sources of vitamin D [118]. Positive effects of Vitamin D supplementation are particularly realised in Vitamin D deficient populations [119].

Vitamin K₂ is a fat-soluble menaquinone vitamin [120]. Vitamin K₂ is an activator of gammacarboxy glutamic acid proteins (Gla-proteins), a group of proteins with many biological functions including inhibition of vascular calcification and promoting bone formation [121]. It changes the magnesium calcium balance in the muscle by helping transport of calcium from muscle to bones and teeth [122]. Vitamin K₂ may also play a role in the health of skeletal muscles by improving cell proliferation and muscle regeneration [123]. Deficiency of vitamin K₂ in adults may be contributing to poorer vascular and bone health [124]. This deficiency is related to the interaction of various factors, such as reduced dietary intake, alteration of intestinal absorption or production, and the impact of Western diet on the gut microbiome.

Importance of skin and fascia in myofascial pain

Experience dictates that dysfunctions in muscles, fascia and scars are common in the pediatric population and are significant contributors to pediatric chronic pain [10]. The skin is the largest organ of the body and serves as a barrier and sensor between the body and the external environment. It is electrically active, contains many nerve elements and has connections to the nervous system including the autonomic nervous system [125,126]. When the skin is injured, the healing process leads to the formation of scar tissue. Remodelling of the scar and the deposition of type 1 collagen increases the strength of the tissue but decreases its elasticity. This can lead to reduced mobility and flexibility of not only skin, but also the underlying fascia and muscle, which may present as pain. Scar tissue is associated with increase nerves and neuropeptides, and nociceptors in scarred tissues can produce pathological reflex arc [32]. The release of scars with micro-needling techniques have been shown to produce relief of chronic pain [10].

The fascia is recognized as a significant contributor to chronic pain [127-130]. The most up to date definition of fascia describes it as a sheath, a sheet or any number of dissectible aggregations of connective tissue that forms beneath the skin [131]. However, it is the definition of the fascial system that highlights its importance in biomechanical regulation. The fascial system consists of the three-dimensional continuum of soft collagen containing loose and dense fibrous connective tissues that permeate the body. It incorporates elements such as adipose tissue, adventitia, neurovascular sheaths, aponeurosis, deep and superficial fascia, epineurium, joint capsules, ligaments, membranes, meninges, myofascial expansions, periosteum, retinacula, septa, tendons, visceral fascia, and all the intramuscular and intermuscular connective tissues including endo-/peri-/epi-mysium. The fascial system surrounds, interweaves between, and interpenetrates all organs, muscles, bones and nerve fibres, endowing the body with a functional structure and providing an environment that enables all body systems to operate in an integrated manner [131]. As the fascia envelops every structure within the body it creates a structural continuity that provides form and function to every tissue and organ [132-134]. It varies in thickness, function, composition, and direction depending on its location and purpose [132]. It is

innervated by the autonomic nervous system [133] and can be considered as a sense organ of human biomechanics [133,135,136]. Injury reduces the flexibility of fascia. The subsequent defective fascial sliding generates anomalous tension which affects the fascial continuum leading to pain and progressive immobility [32,137].

As all structures of the human body are intricately connected through skin and the myofascial system, myofascial release (often at a distant site) can result in improvement of pain and flexibility and range of motion [10] but it is imperative that this is combined in a multidisciplinary approach to address the whole biopsychosocial aspects of pain.

Multidisciplinary approach to pediatric chronic pain

The gold standard of care in pediatric chronic pain is an interdisciplinary approach with a team consisting of a chronic pain physician, nurse, physiotherapist and psychologist [138]. The established model is often described as the 3P approach – Pharmacology, Psychology and Physiotherapy. The balance of the individual components is dependent on the individual and the impacts of their pain as no two pain experiences are identical. A goal-directed, individualized plan takes into consideration the pain type and its effect on the psychosocial function of the child. The success of treatment is highly dependent on early intervention as well as integration into the multidisciplinary care plan. Successful restoration to normal function and less pain is dependent on the patient's motivation to initiate and maintain their progress with the prescribed care plan. A significant component of the care plan is education, reassurance, and self-management strategies (see www.mycarepath.ca [49]).

Physiotherapy aims to help the patient restore lost function, remain physically active, stretch daily and to improve strength, flexibility and range of motion. This needs to be introduced in a paced manner (see [mycarepath.ca](http://www.mycarepath.ca) pacing video [139]) Physiotherapy always needs to be targeted to the individual patient's needs and goals [140], but, in CMP, also needs to incorporate stretching and massage.

Switching mechanisms from inflammation to resolution of inflammation is now known to be an active process dependent on a new class of endogenous mediators called resolvins [141,142]. Resolvins are lipid molecules derived from polyunsaturated fatty acids and influence the anti-inflammatory process. Stretching of tissues has been shown to increase resolvin levels [143].

Massage is associated with pain reduction in children and adolescents [144–147]. It is postulated that this works through either the Gate control theory [148], stimulation of pressure receptors impacting vagal tone and serotonin [149], decreased substance P from decreased stress responses, and/or increased oxytocin release [150]. It is our clinical experience that massage is particularly effective in children and adolescents with a confirmed myofascial component to their pain. In particular, massage becomes an extremely valuable tool when interventional techniques are not indicated due to needle aversion or age and developmental restrictions.

Psychology plays a very important role in the multi-modal management of chronic pain. The pain experience is greatly influenced by a patient's beliefs, behaviors, social interactions and mindset. Cognitive behaviour therapy (CBT), relaxation techniques can help reduce pain, improve mood, and improve sleep. Muscle relaxation

techniques are particularly helpful in CMP. Psychologists often need to engage family members in the treatment plan to reinforce positive behaviours [138] and liaise with school stakeholders to encourage return to academic activities.

Pharmacologic therapy can be extremely useful as a part of the multi-modal approach. The main goal of pharmacological therapy is to minimize pain enough to enable function and physiotherapy to occur. Successful pharmacological therapy requires consideration of many factors including the pathophysiology of pain, the drug's mechanism of action and side effect profile, and treatment goals. However, the clinician must be careful to avoid placing too much emphasis on using medications alone to treat pain. It is increasingly recognized that pharmacological approaches for chronic pain are woefully ineffective and are associated with significant side effect profiles [151]. Pharmacotherapy has been described as the “weakest link in the therapeutic chain” [152] for pediatric chronic pain management as there is very limited evidence to support efficacy [153–156]. Reliance on opioid medications for treating chronic pain has been a key contributor to the current North American opioid crisis. This is not isolated to adults; a study looking at pediatric patients (aged 2-18) with myalgia and myositis identified that 20% of them were prescribed opioids and 25% were on multiple medications including steroids, anti-depressants and muscle relaxants [19]. Opioid prescriptions in the pediatric population doubled between 1990 and 2010 [157]. Prescription opioids have limited utility in the management of adult chronic pain [158,159] and are associated with significant opioid side effects [160] including opioid use disorder, opioid related overdoses and death. It is imperative that availability and accessibility of non-pharmacological techniques for chronic pain are improved to reduce the need for prescription of opioid medications [161].

The key to the multidisciplinary 3P approach is to keep it simple and de-medicalize. The restoration of normal function should be emphasized as the primary goal. In pediatric patients, this approach has been proven to be effective to decrease pain, improve physical function, mood and school attendance. Additionally, there are positive societal benefits including decreased healthcare utilization and parental workday absence [162–173]. With this 3P approach, clinical experience indicates that improvements in physical functioning seem to precede improvements in pain [163]. Why this may occur may centre on the benefits of exercise on mood, skeletal muscle, metabolic haemostasis and the gut microbiome, as outlined above.

When a myofascial component of pain is diagnosed using a myoActivation assessment, the 3P approach of care is instituted. Emphasis is placed on return to physical functioning with the help of massage therapy and paced physiotherapy. An anti-inflammatory and antioxidant diet, supplemented with Omega-3, is recommended [72]. Nutraceutical supplementation is recommended related to widespread dietary deficiencies, principally with magnesium, vitamin K₂ and Vitamin D for their role in muscle health. These multi-faceted measures often result in a noticeable decrease in CMP at follow-up a month later. Repeated myoActivation physical examinations help direct subsequent physiotherapy and massage therapy, especially if myoActivation is deemed not appropriate due to needle aversion or developmental, age or mood issues. At each follow-up visit, the myoActivation exam is repeated to evaluate and demonstrate improvement or change in myofascial distortion. With ongoing

myofascial components of pain the next step to treatment may involve myoActivation, dependent on the child's age and developmental profile. If myoActivation is considered to be appropriate for the treatment of a patient's myofascial pain, the process is introduced during the initial assessment and supported with verbal and written information.

myoActivation in the pediatric population

This approach represents a paradigm shift in our approach to treating pediatric CMP. myoActivation has become a valuable assessment and therapeutic tool in the chronic pain management toolbox. We emphasize that myoActivation is performed only after we have explored all conservative methods including psychology support, dietary changes, muscle health supplements, physiotherapy and massage. We have observed the advantages of myoActivation with immediate changes in the patient's pain intensity, flexibility and fluidity of movement with no reliance on opioids or other analgesic medications. The technique is low cost, low harm and can be undertaken in an office setting. We believe myoActivation can be a useful technique in the pediatric pain physician's armamentarium to treat chronic myofascial pain.

There are several unique challenges associated with using this technique in the pediatric population. The assessment process for young children may be hindered by their level of cooperation and ability to follow commands. The therapeutic component cannot be undertaken in this age group without appropriate procedural sedation. For the non-verbal patient the clinician needs to rely heavily on parental or guardian history and observations and to use his or her clinical experience to determine the most important dysfunction at myofascial sites and again procedural sedation may need to be employed. Careful consideration must be taken in pediatric patients who are needle averse or have procedural anxiety to determine the risk benefit analysis of myoActivation on an individual basis.

To prevent needle-related pain in pediatric patients, the clinician can employ a variety of non-pharmacological techniques including distraction, diaphragmatic breathing techniques [174], music, virtual reality or mobile devices. Pharmacological modalities can be added when psychological methods are considered insufficient to address the patient's anxiety and needle-related pain. Topical anesthetic cream (for example EMLA) can be applied to the target sites (especially scars) an hour before the appointment to minimize needle pain. Oral benzodiazepines can be useful for anxiolysis in particularly anxious children and adolescents. Lorazepam can be given orally or sublingually to the patient prior to the appointment so that the maximum effect is reached during the myoActivation session. If the above methods are not adequate, IV sedation with appropriate anaesthetic monitoring can be utilized.

Conclusion

In this case series we have demonstrated the benefits of using myoActivation as part of a multi-disciplinary approach in pediatric patients with CMP. myoActivation has transformed our approach to assessing and managing pediatric myofascial pain. However, adoption in the current clinical climate will require a complete change in culture not only in how we take a patient history and examination but also acceptance of the crucially important role of fascia, scars and MTP's in a pain presentation.

According to Stephen George, physiotherapist: "Having a map of Detroit is not helpful when navigating Chicago... our profession must radically change entrenched education, research, and practice patterns"[175].

The move to acceptance of this technique will require robust prospective trials to garner qualitative and quantitative data to support its utility. Additionally, we must determine the long-term outcomes of the procedure with regards to efficacy and safety. The pathophysiology of myofascial pain will also need to be further elucidated. An improved understanding and an increased in established evidence of this condition will improve the education and training of healthcare providers.

Through the case series, we have provided some insight into myoActivation care as well as common barriers and pitfalls to using this therapeutic system in the pediatric population. We hope that this review provides clinicians with valuable insight into pediatric myofascial pain and potential strategies to treat this vulnerable population. Future extensive research and audit are needed to truly demonstrate the utility of myoActivation in the pediatric chronic pain population.

References

1. Breivik, H., Collett, B., Ventafridda, V., Cohen, R., Gallacher, D. (2006) Survey of chronic pain in Europe: prevalence, impact on daily life, and treatment. *Eur J Pain*, 10 (4): 287-333.
2. Friedrichsdorf, SJ., Giordano, J., Dakoji, KD., Warmuth, A., Daughtry, C., Schulz, CA. (2016) Chronic Pain in Children and Adolescents: Diagnosis and Treatment of Primary Pain Disorders in Head, Abdomen, Muscles and Joints. *Child. (Basel, Switzerland)*, 3(4): pii: E42.
3. King, S., Chambers, CT., Huguet, A., MacNevin, RC., McGrath, PJ., Parker, L., et al. (2011) The epidemiology of chronic pain in children and adolescents revisited: a systematic review. *Pain*, 152 (12): 2729-2738.
4. van Dijk, A., McGrath, P., Pickett, W., VanDenKerkhof, EG. (2006) Pain prevalence in nine- to 13-year-old schoolchildren. *Pain Res Manag*, 11(4): 234-240.
5. O'Sullivan, PB., Beales, DJ., Smith, AJ., Straker, LM. (2012) Low back pain in 17 year olds has substantial impact and represents an important public health disorder: a cross-sectional study. *BMC Public Health*, 12: 100.
6. Swain, N., Johnson, M. (2014) Chronic pain in New Zealand: a community sample. *N Z Med J*, 127(1388): 21-30.
7. Huguet, A., Miró, J. (2008) The severity of chronic pediatric pain: an epidemiological study. *J Pain*, 9(3): 226-236.
8. Perquin, CW., Hazebroek-Kampschreur, AA., Hunfeld, JA., Bohnen, AM., van Suijlekom-Smit, LW., Passchier, J., et al. (2000) Pain in children and adolescents: a common experience. *Pain* 87(1): 51-58.
9. Varni, JW., Burwinkle, TM., Limbers, CA., Szer, IS. (2007) The PedsQL as a patient-reported outcome in children and adolescents with fibromyalgia: an analysis of OMERACT domains. *Health Qual Life Outcomes*, 5: 9
10. Lauder, GR., West, N., Siren, G. (2019) myoActivation: A structured process for chronic pain resolution. *Pain Treatment*.
11. Becker, AJ., Heathcote, LC., Timmers, I., Simons, LE. (2018) Precipitating events in child and adolescent chronic musculoskeletal pain. *Pain rep*, 3(suppl 1): e665.
12. Hunfeld, JA., Perquin, CW., Duivenvoorden, HJ., Hazebroek-Kampschreur, AA., Passchier, J., van Suijlekom-Smit, LW., et al. (2001) Chronic pain and its impact on quality of life in adolescents and their families. *J Pediatr Psychol*, 26(3): 145-153.

13. Palermo, TM. (2009) Assessment of chronic pain in children: current status and emerging topics. *Pain Res Manag*, 14(1): 21–26.
14. Sled, M., Eccleston, C., Beecham, J., Knapp, M., Jordan, A. (2005) The economic impact of chronic pain in adolescence: methodological considerations and a preliminary costs-of-illness study. *Pain*, 119(1–3): 183–190.
15. Campbell, F., Stinson, J., Ouellette, C., Ostapets, V., Salisbury, G. (2018) The association between pediatric chronic pain clinic attendance and health care utilization: A retrospective analysis. *Can J Pain*, 2(1): 30–36.
16. Groenewald, CB., Wright, DR., Palermo, TM. (2015) Health care expenditures associated with pediatric pain-related conditions in the United States. *Pain*, 156(5): 951–957.
17. Hogan, ME., Taddio, A., Katz, J., Shah, V., Krahn, M. (2016) Incremental health care costs for chronic pain in Ontario, Canada: a population-based matched cohort study of adolescents and adults using administrative data. *Pain*, 157(8): 1626–1633.
18. Fearon, P., Hotopf, M. (2001) Relation between headache in childhood and physical and psychiatric symptoms in adulthood: national birth cohort study. *BMJ*, 322(7295): 1145.
19. Gmuca, S., Xiao, R., Weiss, PF., Sherry, DD., Knight, AM., Gerber, JS. (2018) Opioid Prescribing and Polypharmacy in Children with Chronic Musculoskeletal Pain. *Pain Med*, 20(3): 495–503.
20. Brattberg, G. (2004) Do pain problems in young school children persist into early adulthood? A 13-year follow-up. *Eur J Pain*, 8(3): 187–199.
21. Jones, GT., Silman, AJ., Power, C., Macfarlane, GJ. (2007) Are common symptoms in childhood associated with chronic widespread body pain in adulthood? Results from the 1958 British Birth Cohort Study. *Arthritis Rheum*, 56(5): 1669–1775.
22. Walker, LS., Dengler-Crish, CM., Rippel, S., Bruehl, S. (2010) Functional abdominal pain in childhood and adolescence increases risk for chronic pain in adulthood. *Pain*, 150(3): 568–572.
23. Antonaci, F., Voiticovschi-Iosob, C., Di Stefano, AL., Galli, F., Ozge, A., Balottin, U. (2014) The evolution of headache from childhood to adulthood: a review of the literature. *J Headache Pain*, 15(1): 15.
24. Hestbaek, L., Leboeuf-Yde, C., Kyvik, KO., Manniche, C. (2006) The course of low back pain from adolescence to adulthood: eight-year follow-up of 9600 twins. *Spine (Phila. Pa. 1976)*, 31(4): 468–472.
25. Eccleston, CM., Maleson, P. (2003) Managing chronic pain in children and adolescents. We need to address the embarrassing lack of data for this common problem. *BMJ*, 326 (7404): 1408–1409.
26. Noel, M., Beals-Erickson, SE., Law, EF., Alberts, NM., Palermo, TM. (2016) Characterizing the Pain Narratives of Parents of Youth With Chronic Pain. *Clin J Pain*, 32(10): 849–858.
27. Perrot, S., Cohen, M., Barke, A., Korwisi, B., Rief, W., Treede, RD., et al. (2019) The IASP classification of chronic pain for ICD-11: chronic secondary musculoskeletal pain. *Pain*, 160(1): 77–82.
28. Huguenin, LK. (2004) Myofascial trigger points: the current evidence. *Phys Ther Sport*, 5(1): 2–12.
29. Shah, JP., Thaker, N., Heimur, J., Aredo, JV., Sikdar, S., Gerber, L. (2015) Myofascial Trigger Points Then and Now: A Historical and Scientific Perspective. *PMR*, 7(7): 746–761.
30. Liu, L., Huang, QM., Liu, QG., Ye, G., Bo, CZ., Chen, MJ., Li, P. (2015) Effectiveness of dry needling for myofascial trigger points associated with neck and shoulder pain: a systematic review and meta-analysis. *Arch Phys Med Rehabil*, 96(5): 944–955.
31. Akamatsu, FE., Yendo, TM., Rhode, C., Itezerote, AM., Hojaij, F., Andrade, M., et al. (2017) Anatomical Basis of the Myofascial Trigger Points of the Gluteus Maximus Muscle. *Biomed Res Int*, 2017: 4821968.
32. Bordoni, B., Zanier, E. (2013) Skin, fascias, and scars: symptoms and systemic connections. *J Multidiscip Healthc*, 7: 11–24.
33. Leijnse, JN., Rietveld, AB. (2013) Left shoulder pain in a violinist, related to extensor tendon adhesions in a small scar on the back of the wrist. *Clin. Rheumatol*, 32(4): 501–506.
34. Yoshida, S., Hagiwara, Y., Tsuchiya, M., Shinoda, M., Koide, M., Hatakeyama, H., et al. (2018) Involvement of neutrophils and interleukin-18 in nociception in a mouse model of muscle pain. *Mol Pain*, 14: 174480691875728.
35. Vázquez-Delgado, E., Cascos-Romero, J., Gay-Escoda, C. (2009) Myofascial pain syndrome associated with trigger points: a literature review. (I): Epidemiology, clinical treatment and etiopathogeny. *Med Oral Patol Oral Cir Bucal*, 14(10): e494–e498.
36. Dannecker, EA., Gagnon, CM., Jump, RL., Brown, JL., Robinson, ME. (2004) Self-care behaviors for muscle pain. *J Pain*, 5(9): 521–527.
37. Woolf, AD., Erwin, J., March, L. (2012) The need to address the burden of musculoskeletal conditions. *Best Pract Res Clin Rheumatol*, 26(2): 183–224.
38. Hakala, P., Rimpelä, A., Salminen, JJ., Virtanen, SM., Rimpelä, M. (2002) Back, neck, and shoulder pain in Finnish adolescents: national cross sectional surveys. *BMJ*, 325(7367): 743.
39. Sperotto, F., Brachi, S., Vittadello, F., Zulian, F. (2015) Musculoskeletal pain in schoolchildren across puberty: a 3-year follow-up study. *Pediatr Rheumatol Online J*, 13: 16.
40. Hugué, A., Tougas, ME., Hayden, J., McGrath, PJ., Stinson, JN., Chambers, CT., et al. (2016) Systematic review with meta-analysis of childhood and adolescent risk and prognostic factors for musculoskeletal pain. *Pain*, 157(12): 2640–2656.
41. Silva, GR., Pitangui, AC., Xavier, MK., Correia-Júnior, MA., De Araújo, RC. (2016) Prevalence of musculoskeletal pain in adolescents and association with computer and videogame use. *J Pediatr (Rio. J)*, 92(2): 188–196.
42. Queiroz, LB., Lourenço, B., Silva, LEV., Lourenço, DMR., Silva, CA. (2018) Musculoskeletal pain and musculoskeletal syndromes in adolescents are related to electronic devices. *J Pediatr (Rio. J)*, 94(6): 673–679.
43. Leino-Arjas, P., Rajaleid, K., Mekuria, G., Nummi, T., Virtanen, P., Hammarström, A. (2018) Trajectories of musculoskeletal pain from adolescence to middle age: the role of early depressive symptoms, a 27-year follow-up of the Northern Swedish Cohort. *Pain*, 159(1): 67–74.
44. Jones, GT., Macfarlane, GJ. (2005) Epidemiology of low back pain in children and adolescents. *Arch Dis Child*, 90(3): 312–326.
45. Salminen, JJ. (1984) The adolescent back. A field survey of 370 Finnish schoolchildren. *Acta Paediatr Scand Suppl*, 315: 1–122.
46. Oksanen, AM., Laimi, K., Löyttyniemi, E., Kunttu, K. (2014) Trends of weekly musculoskeletal pain from 2000 to 2012: National study of Finnish university students. *Eur J Pain*, 18(9): 1316–1322.
47. Mikkelsen, M., El-Metwally, A., Kautiainen, H., Auvinen, A., Macfarlane, GJ., Salminen, JJ. (2008) Onset, prognosis and risk factors for widespread pain in schoolchildren: a prospective 4-year follow-up study. *Pain*, 138(3): 681–687.
48. Gobina, I., Villberg, J., Välimaa, R., Tynjälä, J., Whitehead, R., Cosma, A., et al. (2019) Prevalence of self-reported chronic pain among adolescents: Evidence from 42 countries and regions. *Eur J Pain*, 23(2): 316–326.
49. <https://www.mycarepath.ca/>
50. Cassel, EJ. (1982) The Nature of Suffering and the Goals of Medicine. *N Engl J Med*, 306(11): 639–645.
51. Cordell, WH., Keene, KK., Giles, BK., Jones, JB., Jones, JH., Brizendine, EJ. (2002) The high prevalence of pain in emergency medical care. *Am J Emerg Med*, 20(3): 165–169.
52. Lee, YJ., Kim, SH., Chung, SW., Lee, YK., Koo, KH. (2018) Causes of Chronic Hip Pain Undiagnosed or Misdiagnosed by Primary Physicians

- in Young Adult Patients: a Retrospective Descriptive Study. *J Korean Med Sci*, 33(52): e339.
53. Feinberg, BI., Feinberg, RA. (1998) Persistent Pain After Total Knee Arthroplasty: Treatment with Manual Therapy and Trigger Point Injections. *J Musculoskelet Pain*, 6(4): 85-95.
54. Ingber, RS. (1989) Iliopsoas myofascial dysfunction: a treatable cause of "failed" low back syndrome. *Arch Phys Med Rehabil*, 70(5): 382-386.
55. Tay, A., Chau, K., Chan, KF. (2000) Upper Quarter Myofascial Pain Syndrome in Singapore: Characteristics and Treatment. *J Musculoskelet Pain*, 8(4): 49-56.
56. Vadivelu, N., Mitra, S., Hines, RL. (2013) Undergraduate medical education on pain management across the globe. *Virtual Mentor*, 15(5): 421-427.
57. <https://www.cmpa-acpm.ca/en/advice-publications/browse-articles/2019/what-happened-to-the-physical-exam>.
58. Clark, BW., Derakhshan, A., Desai, SV. (2018) Diagnostic Errors and the Bedside Clinical Examination. *Med Clin North Am*, 102(3): 453-464.
59. Roldan, CJ., Hu, N. (2015) Myofascial Pain Syndromes in the Emergency Department: What Are We Missing? *J Emerg Med*, 49(6): 1004-1010.
60. Carnes, D., Parsons, S., Ashby, D., Breen, A., Foster, NE., Pincus, T., et al. (2007) Chronic musculoskeletal pain rarely presents in a single body site: results from a UK population study. *Rheumatology (Oxford)*, 46(7): 1168-1170.
61. Schmidt, CO., Baumeister, SE. (2007) Simple patterns behind complex spatial pain reporting? Assessing a classification of multisite pain reporting in the general population. *Pain*, 133(1-3): 174-182.
62. Lieberman, D. (2014) *The Story of the Human Body: Evolution, Health and Disease*, Penguin.
63. Palanza, P., Parmigiani, S. (2016) Why human evolution should be a basic science for medicine and psychology students. *J Anthropol Sci*, 94: 183-192.
64. D'Brant, J. (2014) GMOs, Gut Flora, the Shikimate Pathway and Cytochrome Dysregulation. *Nutr Perspect J Coun Nutr*, 37(1): 5-12.
65. Tsiaoussis, J., Antoniou, MN., Koliarakis, I., Mesnage, R., Vardavas, CI., Izotov, BN., et al. (2019) Effects of single and combined toxic exposures on the gut microbiome: Current knowledge and future directions. *Toxicol Lett*, 312: 72-97.
66. Esposito, K., Nappo, F., Marfella, R., Giugliano, G., Giugliano, F., Ciotola, M., et al. (2002) Inflammatory cytokine concentrations are acutely increased by hyperglycemia in humans: role of oxidative stress. *Circulation*, 106(16): 2067-2072.
67. Grosicki, GJ., Fielding, RA., Lustgarten, MS. (2018) Gut Microbiota Contribute to Age-Related Changes in Skeletal Muscle Size, Composition, and Function: Biological Basis for a Gut-Muscle Axis. *Calcif Tissue Int*, 102(4): 433-442.
68. Leung, A., Gregory, NS., Allen, LA., Sluka, KA. (2016) Regular physical activity prevents chronic pain by altering resident muscle macrophage phenotype and increasing interleukin-10 in mice. *Pain*, 157(1): 70-79.
69. Mosser, DM., Edwards, JP. (2008) Exploring the full spectrum of macrophage activation. *Nat Rev Immunol*, 8(12): 958-969.
70. Ulmann, L., Hirbec, H., Rassendren, F. (2010) P2X4 receptors mediate PGE2 release by tissue-resident macrophages and initiate inflammatory pain. *EMBO J*, 29(14): 2290-2300.
71. Zhang, JM., An, J. (2007) Cytokines, inflammation, and pain. *Int Anesthesiol Clin*, 45(2): 27-37.
72. Rondanelli, M., Faliva, MA., Miccono, A., Naso, M., Nichetti, M., Riva, A., et al. (2018) Food pyramid for subjects with chronic pain: foods and dietary constituents as anti-inflammatory and antioxidant agents. *Nutr Res Rev*, 31(1): 131-151.
73. Herzig, S., Shaw, RJ. (2018) AMPK: guardian of metabolism and mitochondrial homeostasis. *Nat Rev Mol Cell Biol*, 19(2): 121-135.
74. Chan, JSY., Liu, G., Liang, D., Deng, K., Wu, J., Yan, JH. (2019) Special Issue - Therapeutic Benefits of Physical Activity for Mood: A Systematic Review on the Effects of Exercise Intensity, Duration, and Modality. *J Psychol*, 153(1): 102-125.
75. Anderson, E., Shivakumar, G. (2013) Effects of exercise and physical activity on anxiety. *Front psychiatry*, 4: 27.
76. Rimmele, U., Zellweger, BC., Marti, B., Seiler, R., Mohiyeddini, C., Ehlert, U., et al. (2007) Trained men show lower cortisol, heart rate and psychological responses to psychosocial stress compared with untrained men. *Psychoneuroendocrinology*, 32(6): 627-635.
77. Bobinski, F., Teixeira, JM., Sluka, KA., Santos, ARS. (2018) Interleukin-4 mediates the analgesia produced by low-intensity exercise in mice with neuropathic pain. *Pain*, 159(3): 437-450.
78. Lima, LV., Abner, TSS., Sluka, KA. (2017) Does exercise increase or decrease pain? Central mechanisms underlying these two phenomena. *J Physiol*, 595(13): 4141-4150.
79. Ehrman, J., Gordon, P., Visich, P., Keteyian, S. (2018) *Clinical Exercise Physiology*, 4th edn, Human Kinetics.
80. Janssen, I., Leblanc, AG. (2010) Systematic review of the health benefits of physical activity and fitness in school-aged children and youth. *Int J Behav Nutr Phys Act*, 7: 40
81. Landmark, T., Romundstad, P., Borchgrevink, PC., Kaasa, S., Dale, O. (2011) Associations between recreational exercise and chronic pain in the general population: evidence from the HUNT 3 study. *Pain*, 152(10): 2241-2247.
82. Landmark, T., Romundstad, PR., Borchgrevink, PC., Kaasa, S., Dale O. (2013) Longitudinal associations between exercise and pain in the general population--the HUNT pain study. *PLoS One*, 8(6): e65279
83. Zhang, R., Chomistek, AK., Dimitrakoff, JD., Giovannucci, EL., Willett, WC., Rosner, BA., et al. (2015) Physical activity and chronic prostatitis/chronic pelvic pain syndrome. *Med Sci Sports Exerc*, 47(4): 757-764.
84. Heneweer, H., Vanhees, L., Picavet, HS. (2009) Physical activity and low back pain: a U-shaped relation? *Pain*, 143(1-2): 21-25.
85. Holth, HS., Buchardt Werpen, HK., Zwart, JA., Hagen, K. (2008) Physical inactivity is associated with chronic musculoskeletal complaints 11 years later: results from the Nord-Trøndelag Health Study. *BMC Musculoskelet Disord*, 9: 159
86. Martins, DF., Martins, TC., Batisti, AP., Dos Santos Leonel, L., Bobinski, F., Belmonte, LAO., et al. (2018) Long-Term Regular Eccentric Exercise Decreases Neuropathic Pain-like Behavior and Improves Motor Functional Recovery in an Axonotmesis Mouse Model: the Role of Insulin-like Growth Factor-1. *Mol Neurobiol*, 55(7): 6155-6168.
87. Booth, J., Moseley, GL., Schiltenswolf, M., Cashin, A., Davies, M., Hübscher, M. (2017) Exercise for chronic musculoskeletal pain: A biopsychosocial approach. *Musculoskeletal Care*, 15(4): 413-421.
88. Meeus, M., Nijs, J., Wilgen, PV., Noten, S., Goubert, D., Huijnen, I. (2016) Moving on to Movement in Patients with Chronic Joint Pain. *Pain Clin Updat*, 24 (1).
89. Hoffmann, TC., Maher, CG., Briffa, T., Sherrington, C., Bennell, K., Alison, J., et al. (2016) Prescribing exercise interventions for patients with chronic conditions. *CMAJ*, 188(7): 510-518.
90. Mata Diz, JB., de Souza, JR., Leopoldino, AA., Oliveira, VC. (2017) Exercise, especially combined stretching and strengthening exercise, reduces myofascial pain: a systematic review. *J Physiother*, 63(1): 17-22.
91. Bazelmans, E., Bleijenberg, G., Voeten, MJ., van der Meer, JW., Folgering, H. (2005) Impact of a maximal exercise test on symptoms and activity in chronic fatigue syndrome. *J Psychosom Res*, 59(4): 201-218.
92. O'Connor, SR., Tully, MA., Ryan, B., Bleakley, CM., Baxter, GD., Bradley, JM., et al. (2015) Walking exercise for chronic musculoskeletal pain:

- systematic review and meta-analysis. *Arch Phys Med Rehabil*, 96(4): 724-734.
93. Fransen, M., McConnell, S., Harmer, AR., Van der Esch, M., Simic, M., Bennel, KL. (2015) Exercise for osteoarthritis of the knee. *Cochrane Database Syst Rev*, DOI: 10.1002/14651858.CD004376.pub3
94. Kadetoff, D., Kosek, E. (2007) The effects of static muscular contraction on blood pressure, heart rate, pain ratings and pressure pain thresholds in healthy individuals and patients with fibromyalgia. *Eur J Pain*, 11(1): 39-47.
95. Maquet, D., Croisier, JL., Renard, C., Crielaard, JM. (2002) Muscle performance in patients with fibromyalgia. *Joint Bone Spine*, 69(3): 293-299.
96. Schachter, CL., Busch, AJ., Peloso, PM., Sheppard, MS. (2003) Effects of short versus long bouts of aerobic exercise in sedentary women with fibromyalgia: a randomized controlled trial. *Phys Ther*, 83(4): 340-358.
97. Pedersen, BK. (2009) The disease of physical inactivity--and the role of myokines in muscle-fat cross talk. *J Physiol*, 587(pt 23): 5559-5568.
98. Bobinski, F1., Ferreira ,TAA., Córdova, MM., Dombrowski, PA., da Cunha, C., Santo, CCDE., et al. (2015) Role of brainstem serotonin in analgesia produced by low-intensity exercise on neuropathic pain after sciatic nerve injury in mice. *Pain*, 156(12): 2595-2606.
99. Lee, CD., Blair, SN., Jackson, AS. (1999) Cardiorespiratory fitness, body composition, and all-cause and cardiovascular disease mortality in men. *Am J Clin Nutr* 69(3): 373-380.
100. Verbunt, JA., Seelen, HA., Vlaeyen, JW., van de Heijden, GJ., Heuts, PH., Pons, K., et al. (2003) Disuse and deconditioning in chronic low back pain: concepts and hypotheses on contributing mechanisms. *Eur J Pain*, 7(1): 9-21.
101. Gregory, NS., Brito, RG., Fusaro, MCGo., Sluka, KA. (2016) ASIC3 Is Required for Development of Fatigue-Induced Hyperalgesia. *Mol Neurobiol*, 53(2): 1020-1030.
102. Staud, R., Robinson, ME., Price, DD. (2005) Isometric exercise has opposite effects on central pain mechanisms in fibromyalgia patients compared to normal controls. *Pain*, 118(1-2): 176-184.
103. Dailey, DL., Keffala, VJ., Sluka, KA. (2015) Do cognitive and physical fatigue tasks enhance pain, cognitive fatigue, and physical fatigue in people with fibromyalgia?. *Arthritis Care Res (Hoboken)*, 67(2): 288-296.
104. Pires, D., Cruz, EB., Caeiro, C. (2015) Aquatic exercise and pain neurophysiology education versus aquatic exercise alone for patients with chronic low back pain: a randomized controlled trial. *Clin Rehabil*, 29(6): 538-547.
105. Arnaud, MJ. (2008) Update on the assessment of magnesium status. *Br J Nutr*, 99(suppl 3): S24-36.
106. Volpe, SL. (2013) Magnesium in disease prevention and overall health. *Adv Nutr*, 4(3): 378S-83S.
107. Welch, AA., Kelaiditi, E., Jennings, A., Steves, CJ., Spector, TD., MacGregor, A. (2016) Dietary Magnesium Is Positively Associated With Skeletal Muscle Power and Indices of Muscle Mass and May Attenuate the Association Between Circulating C-Reactive Protein and Muscle Mass in Women. *J Bone Miner Res*, 31(2): 317-325.
108. Veronese, N., Demurtas, J., Pesolillo, G., Celotto, S., Barnini, T., Calusi, G., et al. (2019) Magnesium and health outcomes: an umbrella review of systematic reviews and meta-analyses of observational and intervention studies. *Eur J Nutr*, DOI: 10.1007/s00394-019-01905-w.
109. Rosanoff, A., Weaver, CM., Rude, RK. (2012) Suboptimal magnesium status in the United States: are the health consequences underestimated?. *Nut Rev*, 70(3): 153-164.
110. Baaij, JHF., Hoenderop, JG., Bindels, RJ. (2015) Magnesium in man: implications for health and disease. *Physiol Rev*, 95(1): 1-46.
111. Rayssiguier, Y., Libako, P., Nowacki, W., Rock, E. (2010) Magnesium deficiency and metabolic syndrome: stress and inflammation may reflect calcium activation. *Magnes Res*, 23(2): 73-80.
112. Moshfegh, A. et al. (2009) What we eat in America. NHANES 2005-2006: usual nutrient intakes from food and water compared to 1997 dietary reference intakes for vitamin D, calcium, phosphorus, and magnesium. US Department of Agriculture, Agricultural Research Service.
113. Al Alawi, AM., Majoni, SW., Falhammar, H. (2018) Magnesium and Human Health: Perspectives and Research Directions. *Int J Endocrinol*, 9041694.
114. Demay, MB. (2006) Mechanism of vitamin D receptor action. *Ann N Y Acad Sci*, 1068: 204-213.
115. Shea, MK., Booth, SL., Massaro, JM., Jacques, PF., D'Agostino, RB., Dawson-Hughes, B., et al. (2008) Vitamin K and vitamin D status: associations with inflammatory markers in the Framingham Offspring Study. *Am J Epidemiol*, 167(3): 313-320.
116. Bahrami, A., Mazloum, SR., Maghsoudi, S., Soleimani, D., Khayatzadeh, SS., Arekhi, S., et al. (2018) High Dose Vitamin D Supplementation Is Associated With a Reduction in Depression Score Among Adolescent Girls: A Nine-Week Follow-Up Study. *J Diet Suppl*, 15(2): 173-182.
117. Holick, MF. (2002) Vitamin D: the underappreciated D-lightful hormone that is important for skeletal and cellular health. *Curr Opin Endocrinol Diabetes*, 9(1): 87-98
118. Guillemant, J., Taupin, P., Le, HT., Taright, N., Allemandou, A., Pérès, G., et al. (1999) Vitamin D status during puberty in French healthy male adolescents. *Osteoporos. Int*, 10(3): 222-225.
119. Deane, CS., Wilkinson, DJ., Phillips, BE., Smith, K., Etheridge, T., Atherton, PJ. (2017) "Nutraceuticals" in relation to human skeletal muscle and exercise. *Am J Physiol Endocrinol Metab*, 312(4): E282-E299
120. Cunningham, E. (2016) What Is Vitamin K2 and Does It Have an Impact on Bone Health?. *J Acad Nutr Diet*, 116(5): 888.
121. Flore, R., Ponziani, FR., Di Rienzo, TA., Zocco, MA., Flex, A., Gerardino, L., et al. (2013) Something more to say about calcium homeostasis: the role of vitamin K2 in vascular calcification and osteoporosis. *Eur Rev Med Pharmacol Sci*, 17(18): 2433-2440.
122. Weber, P. (2001) Vitamin K and bone health. *Nutrition*, 17(10): 880-887.
123. Rønning, SB., Pedersen, ME., Berg, RS., Kirkhus, B., Rødbotten, R. (2018) Vitamin K2 improves proliferation and migration of bovine skeletal muscle cells in vitro. *PLoS One*, 13(4): e0195432.
124. Schymeinsky, J., Mócsai, A., Walzog, B. (2007) Neutrophil activation via beta2 integrins (CD11/CD18): molecular mechanisms and clinical implications. *Thromb Haemost*, 98(2): 262-273.
125. Di Meglio, P., Perera, GK., Nestle, FO. (2011) The multitasking organ: recent insights into skin immune function. *Immunity*, 35(6): 857-869.
126. O'Brien, GS., Rieger, S., Wang, F., Smolen, GA., Gonzalez, RE., Buchanan, J., et al. (2012) Coordinate development of skin cells and cutaneous sensory axons in zebrafish. *J Comp Neurol* 520 (4): 816-31.
127. Stecco, A., Stern, R., Fantoni, I., De-Caro, R., Stecco, C. (2016) Fascial Disorders: Implications for Treatment. *PM R*, 8(2): 161-168.
128. Schilder, A., Hoheisel, U., Magerl, W., Benrath, J., Klein, T., Treede, RD. (2014) Sensory findings after stimulation of the thoracolumbar fascia with hypertonic saline suggest its contribution to low back pain. *Pain*, 155(2): 222-231.
129. Bednar, DA., Orr, FW., Simon, GT. (1995) Observations on the pathomorphology of the thoracolumbar fascia in chronic mechanical back pain - A microscopic study. *Spine (Phila. Pa. 1976)*, 20(10): 1161-1164.

130. Langevin, HM., James, RF., Cathryn, K., Gary, JB., Ann, CG., Nicole AB., et al. (2011) Reduced thoracolumbar fascia shear strain in human chronic low back pain. *BMC Musculoskelet Disord*, 12: 203.
131. Adstrum, S., Nicholson, H. (2019) A history of fascia. *Clin Anat*, DOI: 10.1002/ca.23371.
132. Bordoni, B., Zanier, E. (2014) Clinical and symptomatological reflections: the fascial system. *J Multidiscip Healthc*, 7: 401–411.
133. Tozzi, P. (2012) Selected fascial aspects of osteopathic practice. *J Bodyw Mov Ther*, 16(4): 503–519
134. Stecco, A., Gesi, M., Stecco, C., Stern, R. (2013) Fascial components of the myofascial pain syndrome. *Cur Pain Headache Rep*, 17(8): 352.
135. Stecco, C., Gagey, O., Belloni, A., Pozzuoli, A., Porzionato, A., Macchi, V., et al. (2007) Anatomy of the deep fascia of the upper limb. Second part: study of innervation. *Morphologie*, 9 (292): 38–43.
136. Vander Wal, J. (2009) The architecture of the connective tissue in the musculoskeletal system-an often overlooked functional parameter as to proprioception in the locomotor apparatus. *Int J Ther Massage Bodywork*, 2(4): 9–23.
137. Langevin, HM., Bishop, J., Maple, R., Badger, GJ., Fox, JR. (2018) Effect of Stretching on Thoracolumbar Fascia Injury and Movement Restriction in a Porcine Model. *Am J Phys Med Rehabil*, 97(3): 187–191.
138. Rabin, J., Brown, M., Alexander, S. (2017) Update in the Treatment of Chronic Pain within Pediatric Patients. *Curr Probl Pediatr Adolesc Health Care*, 47(7): 167–172.
139. <https://www.mycarepath.ca/managing-pain/paced-practiced-and-increasing-activities>
140. Gatchel, RJ., McGeary, DD., McGeary, CA., Lippe, B. (2014) Interdisciplinary chronic pain management: Past, present, and future. *Am Psychol*, 69(2): 119–130.
141. Serhan, CN., Petasis, NA. (2011) Resolvins and Protectins in Inflammation Resolution. *Chem Rev*, 111(10): 5922–5943.
142. Kohli, P., Levy, BD. (2009) Resolvins and protectins: mediating solutions to inflammation. *Br J Pharmacol*, 158(4): 960–971.
143. Berrueta, L., Muskaj, I., Olenich, S., Butler, T., Badger, GJ., Colas, RA., et al. (2016) Stretching Impacts Inflammation Resolution in Connective Tissue *J Cell Physiol*, 231(7): 1621–1627.
144. Ackerman, SL., Anne, LE., Christopher, CD., Elizabeth, AD., Donald IA., Biljana, NH., et al. (2012) Massage for children undergoing hematopoietic cell transplantation: a qualitative report. *Evid Based Complement Alternat Med*, 2012: 792042.
145. Staveski, SL., Boulanger, K., Erman, L., Lin, L., Almgren, C., Journal, C., et al. (2018) The Impact of Massage and Reading on Children’s Pain and Anxiety After Cardiovascular Surgery: A Pilot Study. *Pediatr. Crit Care Med*, 19(8): 725–732.
146. Field, T. (2019) Pediatric Massage Therapy Research: A Narrative Review. *Child (Basel, Switzerland)*, 6 (6): E78.
147. Parlak Gürol, A., Polat, S., Akçay, MN. (2010) Itching, pain, and anxiety levels are reduced with massage therapy in burned adolescents. *J Burn Care Res*, 31(3): 429–432
148. Melzack, R., Wall, PD. (1965) Pain mechanisms: a new theory. *Science*, 150(3699), 971–979.
149. Field, T. (2016) Moderate pressure massage therapy. In *Affective touch and the neurophysiology of CT afferents*. Springer, 385–396.
150. Morhenn, V., Beavin, LE., Zak, PJ. (2012) Massage increases oxytocin and reduces adrenocorticotropin hormone in humans. *Altern Ther Health Med*, 18(6): 11–18.
151. Giummarra, MJ., Gibson, SJ., Allen, AR., Pichler, AS., Arnold, CA. (2015) Polypharmacy and chronic pain: harm exposure is not all about the opioids. *Pain Med*, 16(3): 472–479.
152. Vega, E., Beaulieu, Y., Gauvin, R., Ferland, C., Stabile, S., Pitt, R., et al. (2018) Chronic non-cancer pain in children: we have a problem, but also solutions. *Minerva Anesthesiol*, 84(9): 1081–1092.
153. Cooper, TE., Heathcote, LC., Clinch, J., Gold, JL., Howard, R., Lord, SM., et al. (2017) Antidepressants for chronic non-cancer pain in children and adolescents. *Cochrane database Syst Rev* 8, CD012535.
154. Cooper, TE., Wiffen, PJ., Heathcote, LC., Clinch, J., Howard, R., Krane, E., et al. (2017) Antiepileptic drugs for chronic non-cancer pain in children and adolescents. *Cochrane database Syst Rev*, 8: CD012536.
155. Cooper, TE., Heathcote, LC., Anderson, B., Grégoire, MC., Ljungman, G., Eccleston, C. (2017) Non-steroidal anti-inflammatory drugs (NSAIDs) for chronic non-cancer pain in children and adolescents. *Cochrane database Syst Rev*, 8: CD012537.
156. Cooper, TE., Fisher, E., Gray, AL., Krane, E., Sethna, N., van Tilburg, MA., et al. (2017) Opioids for chronic non-cancer pain in children and adolescents. *Cochrane database Syst Rev*, 7: CD012538
157. Schechter, NL. (2014) Pediatric pain management and opioids: the baby and the bathwater. *JAMA Pediatr*, 168(11): 987–988.
158. Busse, JW., Craigie, S., Juurlink, DN., Buckley, DN., Wang, L., Couban, RJ., et al. (2017) Guideline for opioid therapy and chronic noncancer pain. *CMAJ*, 189(18): E659–E666.
159. Chaparro, LE., Furlan, AD., Deshpande, A., Mailis-Gagnon, A., Atlas, S., Turk, DC. (2014) Opioids compared with placebo or other treatments for chronic low back pain: an update of the Cochrane Review. *Spine (Phila. Pa. 1976)*, 39(7): 556–563.
160. Noble, M., Tregear, SJ., Treadwell, JR., Schoelles, K (2008) Long-term opioid therapy for chronic noncancer pain: a systematic review and meta-analysis of efficacy and safety. *J Pain Symptom Manage*, 35(2): 214–228.
161. Kolodny, A., Frieden, TR. (2017) Ten Steps the Federal Government Should Take Now to Reverse the Opioid Addiction Epidemic. *JAMA*, 318(16): 1537–1538.
162. Randall, ET., Smith, KR., Conroy, C., Smith, AM., Sethna, N., Logan, DE. (2018) Back to Living: Long-term Functional Status of Pediatric Patients Who Completed Intensive Interdisciplinary Pain Treatment. *Clin J Pain*, 34(10): 890–899.
163. Benore, E., Webster, EE., Wang, L., Banez, G. (2018) Longitudinal Analysis of Patient-Reported Outcomes From an Interdisciplinary Pediatric Pain Rehabilitation Program for Children With Chronic Migraine and Headache. *Headache*, 58(10): 1556–1567.
164. Zernikow, B., Ruhe, AK., Stahlschmidt, L., Schmidt, P., Staratzke, T., Frosch, M., et al. (2018) Clinical and Economic Long-Term Treatment Outcome of Children and Adolescents with Disabling Chronic Pain. *Pain Med*, 19(1): 16–28.
165. Evans, JR., Benore, E., Banez, GA. (2016) The Cost-Effectiveness of Intensive Interdisciplinary Pediatric Chronic Pain Rehabilitation. *J Pediatr Psychol*, 41(8): 849–856.
166. Banez, GA., Frazier, TW., Wojtowicz, AA., Buchannan, K., Henry, DE., Benore, E. (2014) Chronic pain in children and adolescents: 24-42 month outcomes of an inpatient/day hospital interdisciplinary pain rehabilitation program. *J Pediatr Rehabil Med*, 7(3): 197–206.
167. Hechler, T., Ruhe, AK., Schmidt, P., Hirsch, J., Wager, J., Dobe, M., et al. (2014) Inpatient-based intensive interdisciplinary pain treatment for highly impaired children with severe chronic pain: randomized controlled trial of efficacy and economic effects. *Pain*, 155(1): 118–128.
168. Logan, DE., Conroy, C., Sieberg, CB., Simons, LE. (2012) Changes in willingness to self-manage pain among children and adolescents and their parents enrolled in an intensive interdisciplinary pediatric pain treatment program. *Pain*, 153(9): 1863–1870.
169. Gauntlett-Gilbert, J., Connell, H., Clinch, J., McCracken, LM. (2013) Acceptance and values-based treatment of adolescents with chronic pain: outcomes and their relationship to acceptance. *J Pediatr Psychol*, 38(1): 72–81.

-
170. Simons, LE., Sieberg, CB., Pielech, M., Conroy, C., Logan, DE. (2013) What does it take? Comparing intensive rehabilitation to outpatient treatment for children with significant pain-related disability. *J Pediatr Psychol*, 38(2): 213-223.
171. Schatman, ME. (2012) Physician complicity in the transformation of pain medicine from a "profession" to a "business": strategies for reversing a growing trend. *Pain Med*, 13(9): 1149-1151.
172. Maynard, CS., Amari, A., Wiczorek, B., Christensen, JR., Slifer, KJ. (2010) Interdisciplinary behavioral rehabilitation of pediatric pain-associated disability: retrospective review of an inpatient treatment protocol. *J Pediatr Psychol*, 35(2): 128-137.
173. Eccleston, C., Morley, S., Williams, A., Yorke, L., Mastroiannopoulou, K. (2002) Systematic review of randomised controlled trials of psychological therapy for chronic pain in children and adolescents, with a subset meta-analysis of pain relief. *Pain*, 99(1-2): 157-165.
174. Uman, LS., Birnie, KA., Noel, M., Parker, JA., Chambers, CT., McGrath, PJ., et al. (2018) Psychological interventions for needle-related procedural pain and distress in children and adolescents. *Cochrane database Syst Rev*, 10: CD005179.
175. George, SZ (2017) Pain Management: Road Map to Revolution. *Phys Ther*, 97(2): 217-226.